

RELATIONSHIP OF THE ETHMOIDAL INFUNDIBULUM, UNCINATE PROCESS, AND NASAL SEPTUM DEVIATION WITH CHRONIC MAXILLARY RHINOSINUSITIS ON PARANASAL SINUS CT SCAN IN MEDAN

Fingga Prahasti Nasution¹, M.Rizky Fachri², Elvita Rahmi Daulay¹, Ferryan Sofyan³

¹Department of Radiology, Faculty of Medicine, Universitas Sumatera Utara

²Mitra Medika Hospital

³Department of Otorhinolaryngology (Ear, Nose, and Throat), Faculty of Medicine, Universitas Sumatera Utara

Received : 01 May 2026

Accepted : 09 June 2026

Received : 10 May 2026

Accepted : 19 June 2026

Abstract

Background: Chronic rhinosinusitis (CRS) is a common sinonasal inflammatory disease, with global prevalence ~10,9% (European Position Paper on Rhinosinusitis and Nasal Polyps 2021). CRS pathogenesis is associated with impaired osteomeatal complex (OMC) drainage, influenced by anatomical variations, e.g. ethmoidal infundibulum (EI) length and width, uncinat process (UP) type, and nasal septal deviation (NSD) degree. This study aims to evaluate the relationship between anatomical variations of the OMC (EI, UP, and NSD) and the occurrence of maxillary CRS based on paranasal sinus (PNS) CT.

Method: cross-sectional design involved 100 maxillary sinuses from patients who underwent PNS CT at Prof. Dr. Chairuddin Panusunan Lubis Hospital. Statistical analysis was performed using Chi-square and Eta correlation tests.

Result: Mean EI length in CRS (5.9 ± 2.7 mm) was shorter than in non-CRS (7.8 ± 2.6 mm, $p < 0.001$), while EI width was greater (2.8 ± 1.1 mm vs. 2.3 ± 0.5 mm, $p < 0.05$). UP type A was most frequent in CRS (47%, $p < 0.001$). $NSD \geq 10^\circ$ was more common in CRS (31%) than in non-CRS (13%, $p < 0.05$).

Conclusion: Anatomical variations of OMC play an important role in predisposition to maxillary CRS. Most patients showed Keros type 2 and Gera type 2, indicating a moderate risk of complications during functional endoscopic sinus surgery. Comprehensive evaluation using PNS CT is essential for safe and effective surgical planning.

Keywords: ethmoidal infundibulum, uncinat process, nasal septal deviation, Keros classification, Gera classification

INTRODUCTION

Chronic rhinosinusitis (CRS) is one of the most common sinonasal inflammatory diseases encountered in clinical practice. It is characterized by persistent symptoms such as nasal obstruction, rhinorrhea, facial pain or pressure, and olfactory dysfunction lasting for more than 12 weeks. The maxillary sinus is the largest of the paranasal sinuses and plays an important role in facial contour formation; it is also the most frequent site of CRS.¹ The prevalence of CRS is approximately 10.9% according to the European Position Paper on Rhinosinusitis and Nasal Polyps (EPOS) 2021.² The pathogenesis of CRS is influenced by multifactorial interactions, including infection, allergy, immunological factors, environmental exposure, and anatomical variations.^{3, 4} Anatomical variations commonly associated with CRS include the length and width of the ethmoidal infundibulum (EI), the type of uncinat process (UP), and the degree of nasal septum deviation (NSD). An abnormal EI length, UP insertion into the lamina papyracea (LP), or $NSD \geq 10^\circ$ may cause obstruction of the osteomeatal complex (OMC), thereby increasing the risk of maxillary CRS.⁵

The main management of CRS that fails medical therapy is Functional Endoscopic Sinus Surgery (FESS). This procedure requires a detailed understanding of sinonasal anatomy, as complications can be serious, such as cerebrospinal fluid leakage. The olfactory fossa (OF) and lateral lamella (LL) are considered high-risk zones during FESS.^{6, 7, 8} To date, studies on anatomical variations of the OMC and their relationship with CRS in Indonesia remain limited. Likewise, comparative data between the Keros and Gera classifications in assessing FESS risk in the local population are still scarce. Therefore, this study was conducted to evaluate the relationship between variations of the EI, UP, and NSD with

the occurrence of maxillary CRS in patients undergoing paranasal sinus CT scans, with the aim of contributing scientific evidence to both diagnostic evaluation and safe surgical planning.

LITERATURE REVIEW

1. Anatomy and Physiology of the Osteomeatal Complex (OMC) and Maxillary Sinus

The maxillary sinus is the largest of the paranasal sinuses and plays a fundamental role in facial contour formation. Physiologically, the health and patency of this sinus depend heavily on the functional clearance and ventilation provided by the osteomeatal complex (OMC). The OMC is not a single anatomical structure but rather a functional unit comprising the maxillary sinus ostium, ethmoidal infundibulum (EI), uncinata process (UP), hiatus semilunaris, and middle turbinate.⁴ The ethmoidal infundibulum acts as the primary channel draining mucus from the maxillary, frontal, and anterior ethmoid sinuses toward the middle meatus. The medial boundary of this pathway is formed by the uncinata process, a thin, crescent-shaped bony projection on the lateral nasal wall. Morphometric disruptions or anatomical variations within these drainage pathways can significantly alter airflow resistance and mucociliary clearance, predisposing the sinus to mucus stasis and chronic inflammation.²

2. Pathophysiology and Prevalence of Chronic Maxillary Rhinosinusitis

Chronic rhinosinusitis (CRS) is one of the most frequently encountered sinonasal inflammatory diseases in clinical practice, characterized by persistent symptoms such as nasal obstruction, rhinorrhea, facial pain or pressure, and olfactory dysfunction lasting for more than 12 weeks. It poses a substantial global health burden, with an estimated prevalence of approximately 10.9% according to the European Position Paper on Rhinosinusitis and Nasal Polyps (EPOS). While the maxillary sinus is recognized as the most frequent site for CRS development, its pathogenesis remains multifactorial, arising from complex interactions between infections, allergies, immunological profiles, environmental exposures, and local anatomical variants.⁴ The mechanical theory of CRS highlights that structural anomalies within the OMC narrow the pre-existing drainage pathways, leading to sinus hypoventilation, localized tissue hypoxia, and impaired ciliary function. This mechanical blockage traps secretions within the maxillary ostium, creating an ideal environment for persistent mucosal edema and initiating a self-perpetuating cycle of chronic tissue inflammation.⁴

3. Impact of OMC Anatomical Variations on Maxillary CRS Development

Detailed evaluations using paranasal sinus computed tomography (CT) have consistently linked specific structural variations of the OMC to an increased predisposition for maxillary CRS:

- **Ethmoidal Infundibulum (EI) Dimensions:** Variations in EI dimensions alter normal physiological drainage patterns. A significantly shorter EI length impairs effective mucociliary transport, thereby accelerating mucus stagnation. Conversely, an increased EI width in CRS patients typically represents a secondary, adaptive change. This fusiform widening or passive dilation is triggered by prolonged secretory pressure, chronic mucosal edema, and inflammatory lateral nasal wall remodeling over time.⁴
- **Uncinate Process (UP) Insertion Types:** The superior attachment pattern of the uncinata process heavily modulates the spatial configuration of the OMC. Type A insertion, where the UP attaches anteriorly to the lamina papyracea, is the most common variant associated with maxillary CRS. This configuration narrows the terminal recess, facilitates opposing mucosal contact, and blocks natural sinus ventilation.⁴
- **Nasal Septal Deviation (NSD):** Severe septal angulation structurally disrupts aerodynamic symmetry within the nasal cavity. Deviations measuring $\geq 10^\circ$ significantly alter airflow patterns, creating localized turbulence and mechanical compression against adjacent middle turbinates or the lateral nasal wall. This mechanical insult impairs clearance on the convex side of the deviation, leading to prolonged mucus stasis and an elevated risk of chronic maxillary sinusitis.³

4. Paranasal Sinus CT Evaluation and Surgical Risk Classifications for FESS

When maximal medical therapy fails to manage CRS adequately, Functional Endoscopic Sinus Surgery (FESS) stands as the primary surgical intervention. Achieving a safe and successful surgical outcome relies on a precise, individualized map of the patient's sinonasal anatomy to avoid iatrogenic injuries. High-resolution paranasal sinus CT scans evaluated in the coronal plane using bone window mode serve as the definitive preoperative roadmap. Special surgical attention must be dedicated to the olfactory fossa and the lateral lamella of the cribriform plate, which are highly vulnerable zones prone to serious complications, such as iatrogenic cerebrospinal fluid (CSF) leakage.⁴

RELATIONSHIP OF THE ETHMOIDAL INFUNDIBULUM, UNCINATE PROCESS, AND NASAL SEPTUM DEVIATION WITH CHRONIC MAXILLARY RHINOSINUSITIS ON PARANASAL SINUS CT SCAN IN MEDAN

Fingga Prahasti Nasution et al

To systematically quantify these surgical risks, two prominent radiological classifications are utilized:

- **Keros Classification:** This system categorizes the depth of the olfactory fossa by measuring the vertical height of the lateral lamella against the cribriform plate. Keros Type 2 represents a moderate depth (4–7 mm), indicating a moderately long and thin lateral lamella that carries a distinct, intermediate risk of unintended intracranial perforation during endoscopic instrumentation.¹
- **Gera Classification:** This newer classification framework assesses risk by measuring the anatomical angle formed between the lateral lamella and the horizontal plane of the cribriform plate. A Gera Tipe 2 configuration reflects a moderate angulation, providing clinicians with crucial geometric data regarding the sloping architecture of the ethmoid roof.²

Integrating a rigorous evaluation of OMC variations alongside objective skull base risk assessments via pre-FESS CT screening is essential to minimize catastrophic orbital or skull base complications while ensuring the restoration of optimal, long-term sinus drainage.²

METHODS

Study design

This study was an analytical observational study with a cross-sectional design conducted at the Radiology Department of Prof. dr. Chairuddin Panusunan Lubis (CPL) Hospital, Medan, from December 2024 to June 2025. The study population consisted of all patients who underwent paranasal sinus CT (CT PNS) at CPL Hospital from January 2022 to December 2024. A total of 100 patients were included, selected using a consecutive sampling technique. Inclusion criteria were age ≥ 18 years, while exclusion criteria included a history of sinonasal surgery or trauma, the presence of sinonasal masses, or congenital craniofacial anomalies.

Measurement of the ethmoidal infundibulum

To measure the length of the ethmoidal infundibulum (EI), the distance between the ostium and the free edge of the uncinete process (UP) was measured and reported in millimeters (mm). To measure the width of the EI, three pathway areas (initiation, middle, and terminal portions) were selected, and the distance between the UP and the medial or inferomedial orbital wall (or Haller cells, if present) was measured in mm (Figures 1a–b). The mean value of the three measurements was calculated to determine the final average EI width (Figures 1c–d).

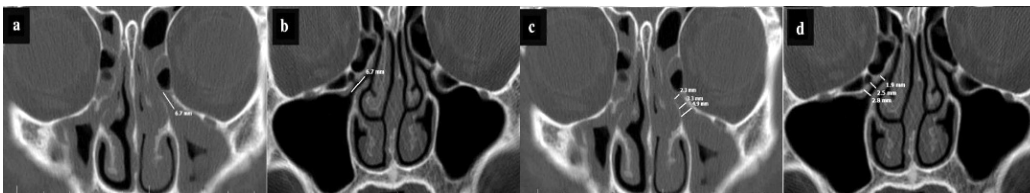


Figure 1. Measurement of the ethmoidal infundibulum length and width: (a, b) length measurement; (c, d) width measurement.

For assessment of the uncinete process (UP), it was classified into three types based on its attachment: attachment to the lamina papyracea (Type A), to the cribriform plate/skull base (Type B), and to the middle turbinate (Type C), as illustrated in the figure.

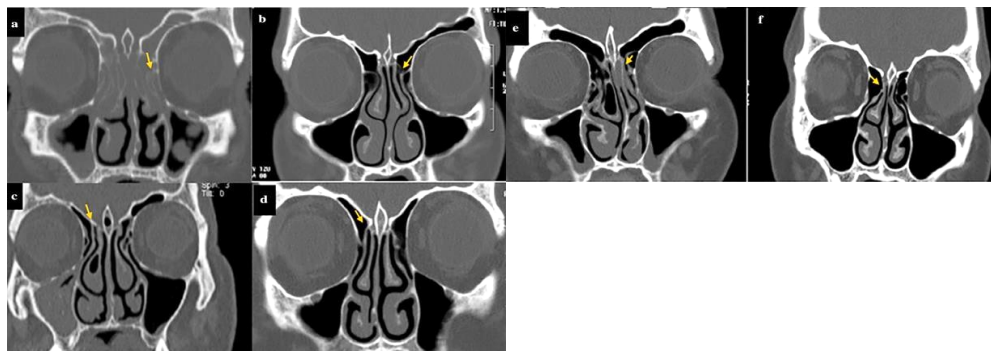


Figure 2. Uncinate process attachment with or without sinusitis: (a, b) attachment to the lamina papyracea (arrows); (c, d) attachment to the cribriform plate (CP) (arrows); (e, f) attachment to the middle turbinate (arrows).

Nasal septum deviation (NSD) was determined by measuring the angle formed between a line drawn from the crista galli to the anterior nasal spine and the point of maximal septal deviation, which was considered the NSD angle. The obtained NSD values were categorized into two groups, $NSD < 10^\circ$ and $NSD \geq 10^\circ$, and these two groups were compared in this study.

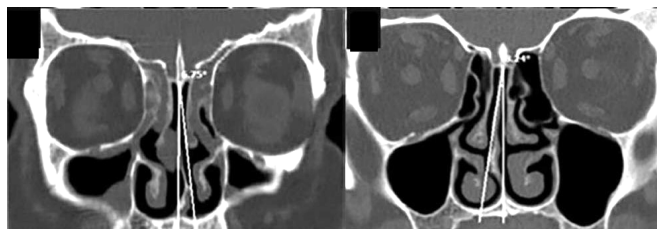


Figure 3. Measure nasal septum deviation degree

Then, the LL height was measured using Keros classification to categorize LL height. Coronal CT films were analyzed in bone window mode, and the results were recorded in a data sheet. Next, the LL angle was measured based on Gera classification by measuring the angle between the LL and the horizontal plane extending from the Posterior Crest (CP).

Statistical Analysis

Data were presented as proportions or percentages, and mean values. Bivariate analysis was conducted using the Chi-Square test and the Eta test. Results with $p < 0.05$ were considered statistically significant.

RELATIONSHIP OF THE ETHMOIDAL INFUNDIBULUM, UNCINATE PROCESS, AND NASAL SEPTUM DEVIATION WITH CHRONIC MAXILLARY RHINOSINUSITIS ON PARANASAL SINUS CT SCAN IN MEDAN

Fingga Prahasti Nasution et al

RESULT

Based on age distribution, the largest group was 26–45 years old, comprising 54 sinuses (54%) with a mean age of 34 ± 13.3 years. The distribution of sex and history of inhalant allergies was relatively balanced.

Table 1. Subject Characteristics

Characteristics	n	%	Mean ± SD
Usia			
17 - 25 years	30	30	34 ± 13,3 years
26 - 45 years	54	54	
46 - 65 years	10	10	
> 65 years	6	6	
Sex			
Male	48	48	
Female	52	52	
History of Inhalant Allergy			
Yes	50	50	
No	50	50	

Based on the table below, it can be seen that in maxillary CRS, the average length of the EI is small, with a mean of 5.9 ± 2.7 mm, while the width is relatively large, with a mean of 2.8 ± 2.4 mm. Meanwhile, the most common UP type in RSK patients was type A (47%), and some maxillary RSK patients were found to have PUNSD (31%).

Table 2. Characteristics of age, sex, occurrence of maxillary CRS, and history of allergy based on EI length and width, UP type, and NSD.

Characteristics	EI (mm)		UP Process			NSD (degree)	
	Length	Width	A	B	C	<10	>10
Age (year)							
17 - 25	5,8±3,2	5,8±3,2	18(18%)	7(7%)	5(5%)	18(18%)	12(12%)
26 - 45	7,1±2,6	2,7±1,1	28(28%)	11(11%)	15(15%)	30(30%)	24(24%)
46 - 65	6,8±2,4	2,6±0,8	7(7%)	3(3%)	0(0%)	6(6%)	4(4%)
> 65	8,7±1,0	3,0±0,8	2(2%)	3(3%)	1(1%)	2(2%)	4(4%)
Sex							
Male	7,3±2,8	2,8±1,1	25(25%)	11(11%)	12(12%)	30(30%)	18(18%)
Female	6,3±2,7	2,4±0,7	30(30%)	13(13%)	9(9%)	26(26%)	26(26%)
Maxillary CRS							
Yes	5,9±2,7	2,8±1,1	47(47%)	3(3%)	4(4%)	23(23%)	31(31%)
No	7,8±2,6	2,3±0,5	8(8%)	21(21%)	17(17%)	33(33%)	13(13%)
History of Inhalant Allergy							
Yes	6,8±2,5	2,6±1,0	28(28%)	11(11%)	11(11%)	30(30%)	20(20%)
No	6,7±3,1	2,6±0,7	27(27%)	13(13%)	10(10%)	26(26%)	24(24%)

Based on the analysis results in the table, there is a relationship between the length and width of the EI and maxillary RSK, with a weak to moderate strength of association. The table also shows a significant relationship between UP type and NSD with the occurrence of maxillary RSK, with $p < 0.001$.

RELATIONSHIP OF THE ETHMOIDAL INFUNDIBULUM, UNCINATE PROCESS, AND NASAL SEPTUM DEVIATION WITH CHRONIC MAXILLARY RHINOSINUSITIS ON PARANASAL SINUS CT SCAN IN MEDAN

Fingga Prahasti Nasution et al

Table 3. Statistical analysis of the mean length and width of the ethmoid infundibulum, uncinete process, and nasal septum deviation.

Variation	Maksilary CRS		Statistical Test
	Yes	No	
Ethmoid Infundibulum			
EI length	5,9±2,7	7,8±2,6	0,351 ^a
EI width	2,8±1,1	2,3±0,5	0,239 ^a
Unsinete process			
Type A	47(47%)	8(8%)	< 0,001 ^b
Type B	3(3%)	21(21%)	
Type C	4(4%)	17(17%)	
Nasal Septum Deviation			
No deviation (<10)	23(23%)	33(33%)	< 0,05 ^c
Deviation (> 10)	31(31%)	13(13%)	

^a Uji Eta, ^b Chi Square, ^c Uji Fisher

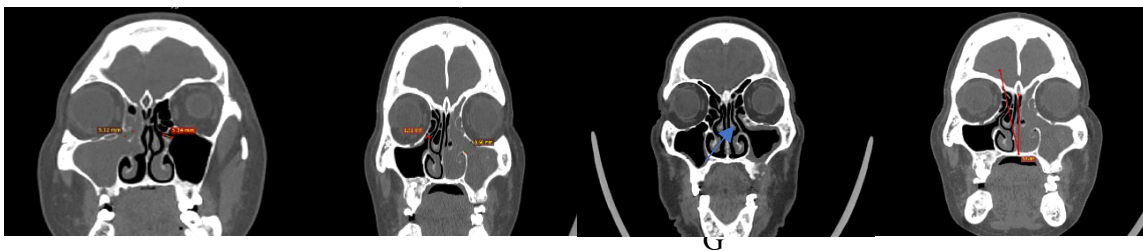


Figure 4. The ethmoid infundibulum is shorter and wider in patients with maxillary CRS (Figures a and b), with UP type A insertion (Figure c), and with NSD (Figure c).

RESULTS AND DISCUSSION

A total of 100 research subjects with a clinical diagnosis of maxillary CRS were successfully included in the analysis. Based on age distribution, the largest age group was 26–45 years (54%), with an overall mean age of 34 ± 13.3 years, and the sex distribution was nearly balanced. The mean EI length across all study subjects was 6–7 mm, with the highest value observed in the >65-year age group (8.7 ± 1.0 mm). The mean EI width was relatively uniform across age groups, ranging from 2.6–3.0 mm. These results indicate that EI length tends to increase with age, whereas EI width is more influenced by local anatomical variations and the degree of lateral nasal wall deviation. In patients with maxillary CRS, the mean EI length (5.9 ± 2.7 mm) was shorter than in non-CRS subjects (7.8 ± 2.6 mm), while the EI width was larger (2.8 ± 1.1 mm vs 2.3 ± 0.5 mm). Eta analysis showed that EI length was associated with the occurrence of maxillary CRS (Eta = 0.351), indicating a moderate strength of association. This suggests that the shorter the EI, the higher the likelihood of developing maxillary CRS. Anatomically, the EI serves as the main drainage pathway for the maxillary sinus through a narrow ostium prone to obstruction. These findings indicate that the combination of a shorter length and a wider width may reflect compensatory widening of the infundibulum due to chronic inflammation and repeated mucosal obstruction. Bolger et al. reported that chronic mucosal inflammation can cause edema and lateral nasal wall remodeling, which alters infundibulum configuration and increases mucus flow resistance. Physiologically, the EI acts as the main drainage route for the maxillary, frontal, and anterior ethmoid sinuses. Morphometric disturbances of the IE, whether narrowing or shortening, have been associated with increased risk of mucus stasis and sinus hypoventilation. Nouraei et al. also emphasized that small changes in EI dimensions can significantly affect airflow resistance and mucus flow patterns. Therefore, evaluating EI length and width on paranasal sinus CT is crucial in determining anatomical predisposition to maxillary CRS.

RELATIONSHIP OF THE ETHMOIDAL INFUNDIBULUM, UNCINATE PROCESS, AND NASAL SEPTUM DEVIATION WITH CHRONIC MAXILLARY RHINOSINUSITIS ON PARANASAL SINUS CT SCAN IN MEDAN

Fingga Prahasti Nasution et al

Conversely, EI width also showed an association with CRS, as patients with CRS had a mean E width of 2.8 ± 1.1 mm, larger than the non-CRS group (2.3 ± 0.5 mm, $\text{Eta} = 0.239$). This association is likely secondary to chronic inflammatory processes that trigger mucosal remodeling and ductal widening, rather than being a primary cause. Al Abri et al. reported similar findings, showing that patients with CRS often exhibit ethmoid infundibulum widening due to secretory pressure and chronic edema, leading to passive dilation. Thus, EI length acts as a predisposing factor, while EI width reflects adaptive post-inflammatory changes. Recognizing these variations via CT has direct implications for the success of FESS.

Radiological observations also revealed that UP type A was most frequently associated with maxillary CRS ($p < 0.001$). Type A has an anterior insertion pattern attached to the lateral lamella of the frontal process, which can narrow the osteomeatal complex (OMC) and impair maxillary sinus ventilation. Several previous studies have reported similar findings. This anatomical configuration facilitates mucociliary obstruction, allowing secretions to become trapped in the maxillary ostium and trigger chronic inflammation. Another significant variable was NSD, with deviations $>10^\circ$ more commonly observed in the CRS group (31%) than in the non-CRS group (13%) ($p < 0.05$). NSD can disrupt airflow and sinus ventilation on the convex side, causing turbulence, mucus stasis, and predisposition to maxillary CRS. Balikci et al. also reported a significant correlation between NSD and increased prevalence of maxillary CRS on CT scans of the paranasal sinuses. These findings confirm that shorter EI length, wider EI width, UP type A insertion, and NSD $>10^\circ$ represent a combination of anatomical variations that increase the risk of maxillary CRS. Comprehensive evaluation of these variations is crucial in preoperative FESS planning to minimize complications and ensure optimal sinus drainage.

CONCLUSION

Complex osteomeatal anatomical variations, particularly EI length/width, UP type A, and NSD $\geq 10^\circ$, are significantly associated with the occurrence of maxillary CRS. Future studies are recommended to use a prospective design with a larger sample size across multiple healthcare centers to increase representativeness. Multivariate analysis should be conducted to control for confounding factors such as age, sex, and allergy history to determine the independent effects of complex osteomeatal anatomical variations on chronic maxillary sinusitis. Furthermore, studies linking radiological findings with clinical outcomes and post-FESS complications will provide more clinically applicable insights.

REFERENCES

1. Fokkens WJ, Lund VJ, Hopkins C, Hellings PW, Kern R, Reitsma S, et al. European Position Paper on Rhinosinusitis and Nasal Polyps 2020. *Rhinology*. 2020 Feb;58(Suppl S29):1–464.
2. Multazar M, Harahap A, Tamin S. Epidemiologi rinosinusitis kronik di RSUP H. Adam Malik Medan. *Indones J Otorhinolaryngol*. 2011;17(3):145–50.
3. Pletcher SD, Goldberg AN, Murr AH, Alt JA. Advances in the understanding of chronic rhinosinusitis: epidemiology, pathophysiology, and recent treatment innovations. *Otolaryngol Clin North Am*. 2016 Jun;49(3):607–25.
4. Lim M, Lew-Gor S, Darby YC, Stansbie JM. Imaging and anatomical correlation in chronic rhinosinusitis: a systematic review. *Clin Otolaryngol*. 2017;42(4):798–806.
5. Abdullah B, Singh K, Abdullah A, Raman R. Imaging of sinonasal anatomical variants in chronic rhinosinusitis: a computed tomographic analysis. *Egypt J Otolaryngol*. 2020;36(1):52.
6. Raza A, Rahim A, Khan M, Aslam A. Association of nasal septal deviation and anatomical variations with chronic rhinosinusitis: CT-based study. *J Coll Physicians Surg Pak*. 2019 Apr;29(4):347–50.
7. Keros P. On the practical value of differences in the level of the lamina cribrosa of the ethmoid. *Arch Otolaryngol*. 1962;74:32–5.
8. Gera R, Mozzanica F, Preti A, Bandi F, Gallo S, Bulfamante AM, et al. A new classification of the lateral lamella of the cribriform plate (Gera classification). *Clin Otolaryngol*. 2010 Dec;35(6):461–7.
9. Yousefi Z, Dalili Kajan Z, Jalali MM, Khosravifard N, Rafiei E. Computed Tomographic Comparison of Length, Width and Angulation of Ethmoidal Infundibulum in Patients with and without Maxillary Sinusitis. *Indian J Otolaryngol Head Neck Surg*. 2022 Oct;74(Suppl 2):1220-1231.

RELATIONSHIP OF THE ETHMOIDAL INFUNDIBULUM, UNCINATE PROCESS, AND NASAL SEPTUM DEVIATION WITH CHRONIC MAXILLARY RHINOSINUSITIS ON PARANASAL SINUS CT SCAN IN MEDAN

Fingga Prahasti Nasution et al

10. Erdem G, et al. Evaluation of Gera classification and its surgical implications in endoscopic sinus surgery. *Clin Anat.* 2019;32(4):560–566.
11. Stammberger H, Lund VJ. Anatomy of the paranasal sinuses. *Rhinology and Skull Base Surgery.* 2019.
12. Mafee MF, Chow JM, Meyers SP. Functional endoscopic sinus surgery: anatomy, CT screening, indications, and complications. *Radiol Clin North Am.* 1993;31(1):1–26.
13. Pynnonen MA, et al. Radiographic correlates of chronic rhinosinusitis severity. *Laryngoscope.* 2015;125(9):2016–2022.
14. Bolger WE, et al. The anatomy of the paranasal sinuses in chronic sinusitis. *Am J Rhinol.* 1991;5(2):85–90.
15. Lund VJ, Stammberger H. FESS: The Messerklinger technique. *Thieme Medical Publishers;* 2018.
16. Nouraei SA, et al. Variations in the paranasal sinus anatomy: impact on sinus disease. *Clin Otolaryngol.* 2019;44(3):375–382.
17. Al Abri R, Bhargava D, Al Balushi Z, et al. Anatomical variations of the ethmoid infundibulum in chronic rhinosinusitis: A CT analysis. *Eur Arch Otorhinolaryngol.* 2020;277(6):1789–95.
18. Landsberg R, Friedman M. Variations of the uncinata process and their relationship to chronic rhinosinusitis: A CT study. *Laryngoscope.* 2017;127(5):1040–1046.
19. Elwany S, Medanni A, Eid M, Aly A. The depth of the olfactory fossa and the risk of cerebrospinal fluid rhinorrhea during endoscopic sinus surgery. *Eur Arch Otorhinolaryngol.* 2017;274(1):403–407.
20. Balikci HH, Gurdal MM, Ozkul MH, et al. Relationship between uncinata process variations and chronic rhinosinusitis: Radiological analysis. *Eur Arch Otorhinolaryngol.* 2019;276(12):3439–3445.
21. Rajashree MS, Mahesh M, Shetty A. Radiological assessment of Keros and Gera classifications and their correlation in chronic rhinosinusitis patients. *Eur Arch Otorhinolaryngol.* 2022;279(12):5675–5682.